



PATIENT

Chibi Ramirez

SPECIES

Canine

BREED

Labrador

SEX

FS

AGE

7yr

WEIGHT

30.2kg

INTERPRETED BY

R. McKenzie Daniel,
DVM, DABVP
(Canine and Feline)

IMAGING PERFORMED BY

Dr. Iacovides

HOSPITAL NAME

Tuxedo Animal
Hospital

REFERRING VET

Dr. Valencia

INVOICE

24274

DATE

03/23/2026

PRESENTING CLINICAL SIGNS

- SQ mass in inguinal area. FNA came back as Mast Cell Tumour
- Abdominal u/s to look for any evidence of systemic disease prior to planning surgery of SQ mass
- Abnormal PE/Chem/CBC/UA Results: Inguinal sq mass which is mast cell tumour

ULTRASONOGRAPHIC EXAMINATION OF THE ABDOMEN

Urinary System

The urinary bladder, trigone, cystourethral junction, and visible pelvic urethra to a depth of 2 cm exhibited normal thickness and tone. Anechoic urine was present in the lumen with no evidence of urine/lumen sediment, mineral, or calculi. The ureteral papillae were normal. The ureters were not visible which is normal. No evidence of inflammatory or neoplastic changes was noted.

Normal size and margination were present in the kidneys. A normal 1:3 cortex / medulla ratio and normal corticomedullary definition were maintained. The echogenicity of the cortex was similar to or slightly less than normal liver parenchyma while the medulla echogenicity was hypoechoic to the cortex with no evidence of pelvic dilation. The left kidney measured 5.6 cm in length. The right kidney measured 5.6 cm in length.

The area of the iliac trifurcation was free of pathology including no evidence of medial iliac or sublumbar lymphadenopathy or masses.

Adrenal Glands

The left adrenal gland was uniform in size and contour with a uniformly hypoechoic parenchyma. The left adrenal gland measured 0.73 cm width at the caudal pole. The right adrenal gland was uniform in size and contour with a uniformly hypoechoic parenchyma. The right adrenal gland measured 0.77 cm width at the caudal pole.

Spleen

The spleen exhibited a finely textured and homogenous parenchyma which was hyperechoic to the liver and renal cortical parenchyma. The capsule was smooth and regular without apparent expansion. The splenic vasculature at the hilus was normal in volume with no evidence of congestion or thrombosis. Acute to chronic inflammatory, neoplastic, or benign parenchyma changes were not noted.

Liver/Gallbladder

The liver was subjectively normal in size, structure, and contour. The liver parenchyma was uniform and hypoechoic to the spleen with a mild coarse echotexture. Normal vascular volume. The hepatic and portal vasculature were normal in appearance without signs of congestion. The gallbladder was non-distended in size with thin walls and primarily anechoic luminal content. The cystic and common bile ducts were normal.

Gastrointestinal

The stomach presented intact wall layering with a normal wall layer ratio. The lumen of the stomach was empty with no signs of ileus, obstruction or foreign material.



PATIENT

Chibi Ramirez

The small intestine presented intact wall layering with 1:3 muscularis/mucosa ratio. The lumen of the small intestine was empty with no signs of mechanical/metabolic ileus, obstruction or foreign material.

Normal visible colon wall layers were present with apparent formed feces in lumen.

SPECIES

Canine

Pancreas

The parenchyma of the left limb, body and right limb of the pancreas presented isoechoic to the adjacent omental fat. A normal curvilinear capsule contour of the pancreas was present. The visible pancreatic duct was normal. No signs of active inflammation or neoplastic disease was evident.

BREED

Labrador

Free Abdomen

No omental masses, overt mesenteric lymphadenopathy or peritoneal effusion was present.

SEX

FS

ULTRASONOGRAPHIC FINDINGS

Primary

- Sonographically normal abdomen

AGE

7yr

INTERPRETATION OF THE FINDINGS & FURTHER RECOMMENDATIONS

No evidence of intra-abdominal or retroperitoneal primary or metastatic neoplastic criteria. Assuming normal clotting status and using 25ga needle, a screening splenic FNA cytology could be considered given confirmed mast cell neoplasia. Otherwise, an oncology consult and sonographic monitoring of the abdomen based on oncology recommendations is suggested.

WEIGHT

30.2kg

INTERPRETED BY

R. McKenzie Daniel,
DVM, DABVP
(Canine and Feline)

IMAGING PERFORMED BY

Dr. Iacovides

HOSPITAL NAME

Tuxedo Animal
Hospital

REFERRING VET

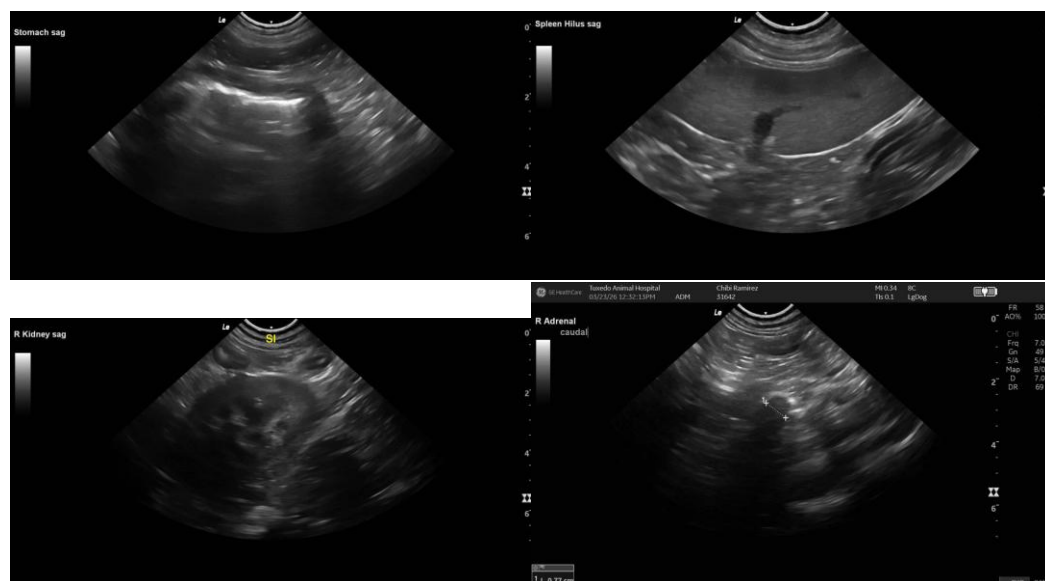
Dr. Valencia

INVOICE

24274

DATE

03/23/2026





PATIENT

Chibi Ramirez

SPECIES

Canine

BREED

Labrador

SEX

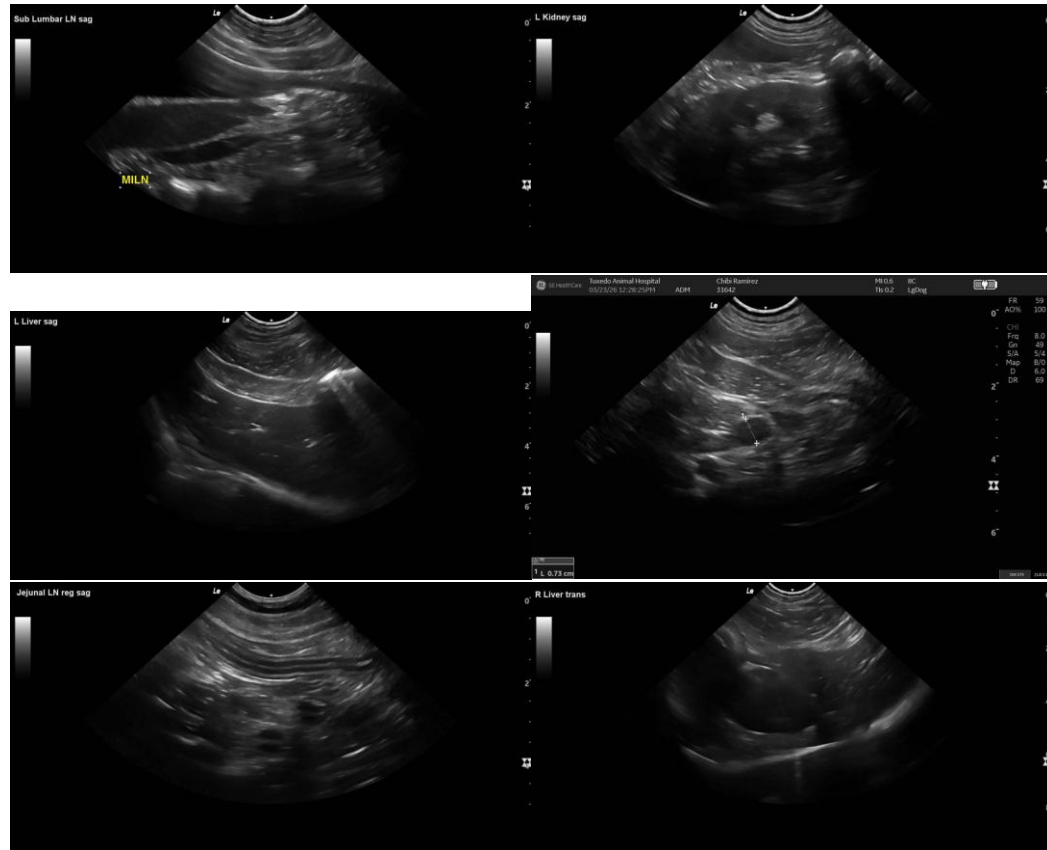
FS

AGE

7yr

WEIGHT

30.2kg



INTERPRETED BY

R. McKenzie Daniel,
DVM, DABVP
(Canine and Feline)

IMAGING PERFORMED BY

Dr. Iacovides

HOSPITAL NAME

Tuxedo Animal
Hospital

REFERRING VET

Dr. Valencia

INVOICE

24274

DATE

03/23/2026

The information and recommendations provided are based on the images presented by the referring veterinarian/sonographer. No evaluation can be communicated regarding pathology that was not visible in the image/video clips provided.

Thank you for this referral. If the clinical or image interpretation does not parallel your findings or if I can be of any further assistance, please contact me.

R. McKenzie Daniel, DVM, DABVP (Canine/Feline Practice)
info@sonopath.com